

## How dogs lap: ingestion and intraoral transport in *Canis familiaris*

A. W. Crompton and Catherine Musinsky

*Biol. Lett.* published online 25 May 2011  
doi: 10.1098/rsbl.2011.0336

---

### References

[This article cites 2 articles, 1 of which can be accessed free](#)

<http://rsbl.royalsocietypublishing.org/content/early/2011/05/23/rsbl.2011.0336.full.html#ref-list-1>

### P<P

Published online 25 May 2011 in advance of the print journal.

### Subject collections

Articles on similar topics can be found in the following collections

[behaviour](#) (2035 articles)

[biomechanics](#) (254 articles)

### Email alerting service

Receive free email alerts when new articles cite this article - sign up in the box at the top right-hand corner of the article or click [here](#)

---

Advance online articles have been peer reviewed and accepted for publication but have not yet appeared in the paper journal (edited, typeset versions may be posted when available prior to final publication). Advance online articles are citable and establish publication priority; they are indexed by PubMed from initial publication. Citations to Advance online articles must include the digital object identifier (DOIs) and date of initial publication.

---

To subscribe to *Biol. Lett.* go to: <http://rsbl.royalsocietypublishing.org/subscriptions>

---

# How dogs lap: ingestion and intraoral transport in *Canis familiaris*

A. W. Crompton\* and Catherine Musinsky

Museum of Comparative Zoology, Department of Organismic Biology, Harvard University, Cambridge, MA 02138, USA

\*Author for correspondence (acrompton@oeb.harvard.edu).

**It has recently been suggested that the mechanism for lifting liquid from a bowl into the oral cavity during lapping is fundamentally different in cats and dogs: cats use adhesion of liquid to the tongue tip while dogs 'scoop' with their backwardly curled tongue. High-speed light videos and X-ray videos show that on the contrary, both cats and dogs use the mechanism of adhesion. Liquid is transported through the oral cavity to the oesophagus, against gravity, on the surface of the tongue as it is drawn upwards, then a tight contact between the tongue surface and palatal rugae traps liquid and prevents its falling out as the tongue is protruded. At least three cycles are needed for intraoral transport of liquid in the dog.**

**Keywords:** *Canis familiaris*; lapping; intraoral transport; high-speed X-ray video

## 1. INTRODUCTION

Reis *et al.* [1] convincingly demonstrate that, at the beginning of a lapping sequence in cats, the tongue tip curls backwards as the tongue extends downwards until the dorsal surface of the tongue comes to rest on, but does not penetrate the liquid surface. They demonstrate that when a cat lifts the tongue, liquid adhering to the dorsal side of the tip is drawn upward, forming a column part of which is captured within the oral cavity as the jaw closes. Consequently, liquid enters the mouth on the dorsal surface of the tongue.

A high-speed video published online by Discovery Networks [2] and viewed by P. Reis and R. Stocker 2010 (personal communication) led them to conclude that dogs also curl the tongue backward, but the tongue tip penetrates the liquid, which then fills a spoon-shaped depression in the ventral surface of the tongue. Liquid appears literally to be scooped into the mouth between the ventral surface of the tongue and the floor of the mouth as the tongue is rapidly withdrawn. However, it is not clear how dogs, lacking cheeks, could transfer liquid scooped into this region of the oral cavity onto the dorsal surface of the tongue where it needs to be for transport to the pharynx and subsequent swallowing [3,4]. Given the overall similarity of the oral region in dogs and cats, a fundamental difference in the mechanism of lapping would not be expected.

Electronic supplementary material is available at <http://dx.doi.org/10.1098/rsbl.2011.0336> or via <http://rsbl.royalsocietypublishing.org>.

## 2. MATERIAL AND METHODS

High-speed video recordings were made of a single domestic dog lapping broth, using a Casio EX-F1 camera at  $300\text{ fs}^{-1}$  (see the electronic supplementary material, video S1). The same dog was recorded with high-speed ( $500\text{ fs}^{-1}$ ) X-ray video (electronic supplementary material, video S2) as it lapped a milk–barium mixture. The videofluoroscopy equipment, located at the X-ray facility at the Concord Field Station of the Museum of Comparative Zoology, consists of a C-arm fluoroscope (OEC model 9400) retrofitted with a 30 cm diameter image intensifier TH9432HX (Dunlee Inc., Aurora, IL, USA) and high-speed Photron Fastcam 1024PCI camera.

Video recordings ( $300\text{ fs}^{-1}$ ) were also made of a single domestic cat lapping milk.

## 3. RESULTS

Figure 1 is based upon selected frames from a video (electronic supplementary material, video S1) recorded at  $300\text{ fs}^{-1}$  of a single lapping cycle of a dog. Outline drawings of the frames highlight significant features. Figure 1*a*, arbitrarily designated the beginning of the cycle, therefore labelled as time 0 ms, shows the liquid filling the spoon-shaped ventral surface of the tongue tip as the tongue begins to withdraw from the liquid surface. As the tongue is withdrawn (figure 1*b,c*) liquid falls out of the 'spoon'. A small amount of this may join the column of liquid adhering to the dorsal surface of the tongue tip as it is carried into the oral cavity (figure 1*d,e*). The jaw closes, trapping the upper column of liquid and the remainder of the column falls away (figure 1*e,f*). The primary agent for moving liquid into the mouth is the adhesion of liquid to the tongue rather than 'scooping' by the tongue.

High-speed X-ray video recorded at  $500\text{ fs}^{-1}$  (electronic supplementary material, video S2) confirms the mechanism described above for transporting liquid to the mouth, but in addition shows how liquid is transported against gravity through the oral cavity. Figure 2*a* shows a single frame from this video and points out the significant features of the oral cavity visible in video frames. The remainder of figure 2 consists of line drawings based upon selected frames of this video. The tongue appears in light grey, the liquid in black and where liquid overlays the tongue in dark grey. It takes three lapping cycles to transfer an aliquot of liquid from a bowl to the posterior region of the oral cavity. In figure 2*b*, arbitrarily designated as the beginning of the lapping cycle and therefore time 0, the tip of the tongue emerges from a slightly opened jaw. The dorsum of the tongue presses against hard palate and traps the liquid ingested in the previous cycle, the second aliquot (figure 2*b*, no. 2), in the hollows of the rugae. Aliquot no. 1, having entered the mouth during the penultimate cycle, has moved to the posterior region of the oral cavity below the soft palate. The proximity between the dorsal surface of the tongue and the palate traps both these aliquots (nos 1 and 2) and prevents them from being carried forward with the tongue as it moves forward to begin the next lapping cycle. As the jaw continues to open, the tongue protrudes and the tongue tip curls backward to penetrate the liquid surface. Figure 2*c* shows the tongue tip's withdrawal from the liquid surface. A column of liquid adheres to the broad downward-facing dorsal surface of the tongue tip, and fills the spoon-shaped depression on the dorsal surface. As the jaw opens, the tongue rapidly withdraws while

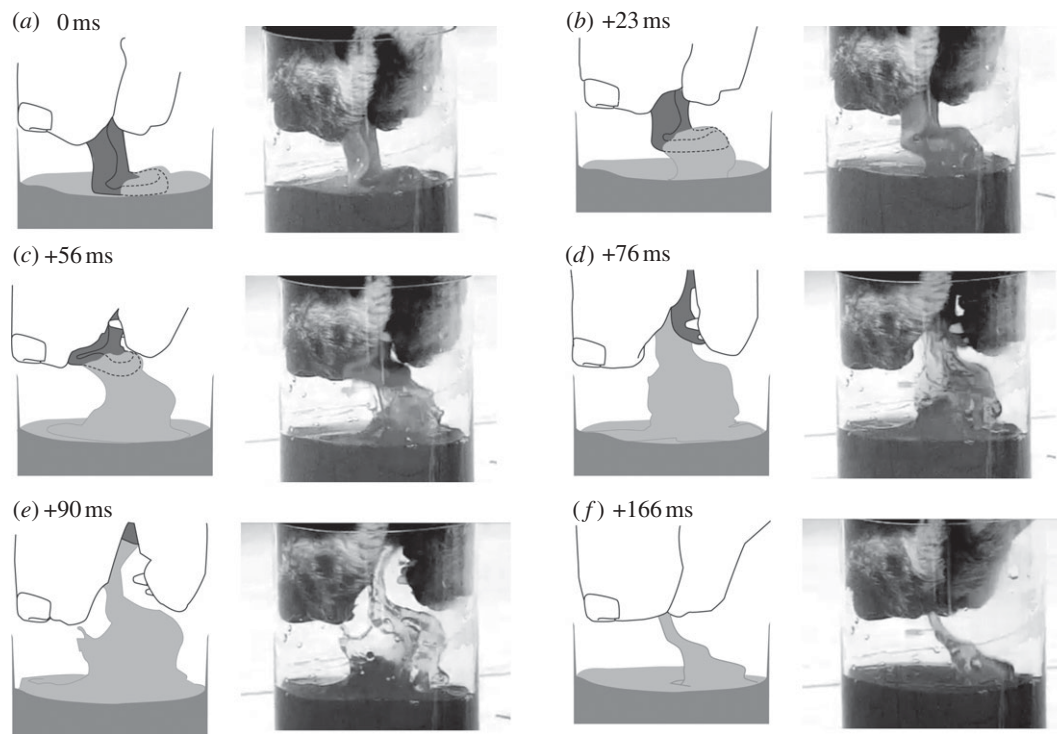


Figure 1. Selected frames from a high-speed video (electronic supplementary material, video S1) of a dog lapping broth, with interpretive outline drawings of each video frame. The timing of each figure relative to the first outline (a) within the sequence is given in milliseconds (ms).

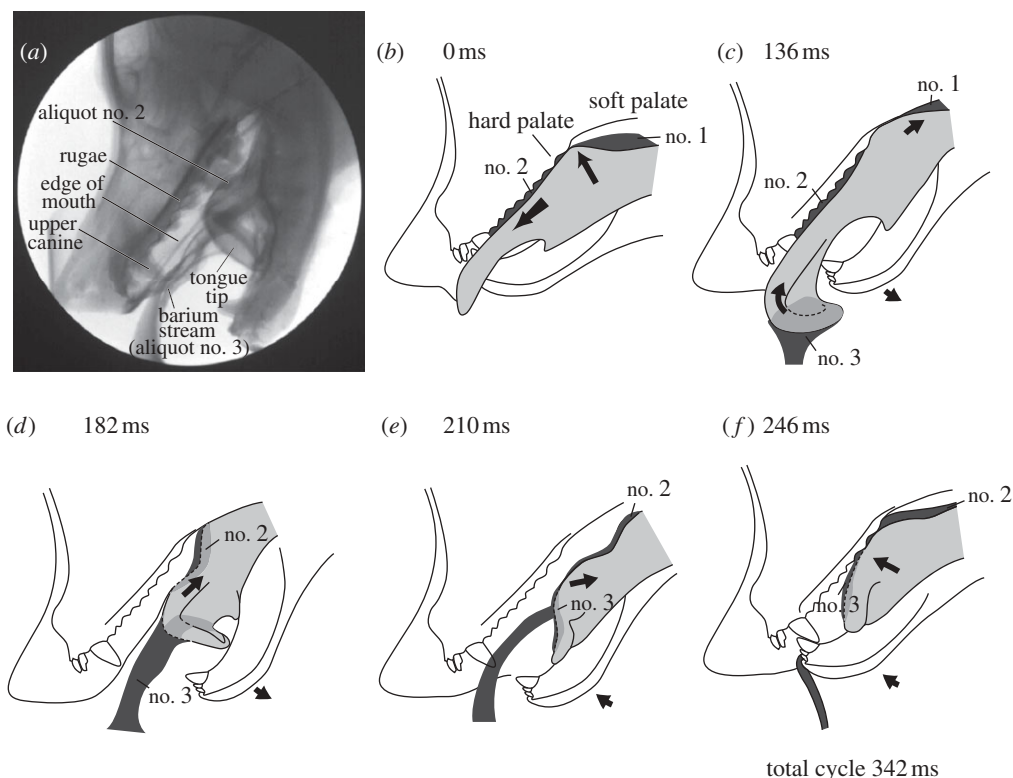


Figure 2. (a) Single frame from X-ray video (electronic supplementary material, video S2) taken in lateral view of dog lapping bariumized milk. This shows a stream of a milk–barium mixture (aliquot no. 3) adhering to the dorsal surface of the tongue tip. (b–f) Outline drawings based on selected fields from a lateral X-ray video (electronic supplementary material, video S2) of a single cycle of dog lapping. The timing of each figure relative to the first outline (b) within the sequence is given in milliseconds (ms). The tongue is shaded grey and the aliquots of liquid (nos 1, 2 and 3) black.

liquid in the ventral surface falls out. In figure 2c, aliquot no. 1 is in the process of being swallowed and aliquot no. 2 is carried backwards on the tongue surface. As maximum gape is reached in figure 2d, the

tongue starts to drop away from the rugae and completely withdraws into the oral cavity. Aliquot no. 3, in the form of a long liquid column, adheres to the tongue tip still forming a right angle bend relative to the

remainder of the tongue body (see also figure 2a). As the jaw begins to close (figure 2e) the tongue surface straightens out and drops further away from both hard and soft palate as it continues to withdraw. Aliquot no. 3 still adheres to the tongue tip and aliquot no. 2 is transported backwards on the tongue surface. As the jaw continues to close (figure 2f), the dorsal surface of the tongue establishes contact with the palate between aliquots nos 3 and 2. The column of liquid outside the mouth drops away. Between figure 2f and the beginning of the next cycle, represented in figure 2b, the tongue elevates and protrudes to trap aliquot no. 3 between the tongue surface and rugae and a new cycle begins. The length of a lapping cycle is 342 ms.

Our high-speed video of cat lapping demonstrated that on many occasions the backwardly curled tongue tip briefly penetrated the liquid surface and picked up liquid in its spoon-shaped ventral surface. As in the dog, this spilled out as the tongue withdrew.

#### 4. DISCUSSION

We conclude that cats and dogs share the same basic mechanism for lifting liquid from a bowl into the oral cavity and transporting it through the oral cavity: liquid adheres to the dorsal surface of the backwardly curled tongue tip. X-ray videos of dog lapping reveal the dexterity with which their tongues trap previously lapped aliquots between the rugae on the roof of their mouths and the dorsal surface of the protruding

tongue, in order to access the next aliquot without losing the previously ingested one [4].

The fact that the dog's tongue tip penetrates more deeply into the liquid than in cats, and consequently sprays more liquid around as the tongue rapidly withdraws, may give the impression that dogs drink by spooning liquids into their mouths. Discovery Network's online video [2] shows a dog lapping clear liquid (water), which is difficult to see adhering to the dorsal surface of the tongue. Dark broth (see the electronic supplementary material, video S1) can be seen more clearly.

We wish to acknowledge the help of Pedro M. Reis and Roman Stocker in the preparation of this letter.

- 1 Reis, P. M., Jung, S., Aristoff, J. M. & Stocker, R. 2010 How cats lap: water uptake by *Felis catus*. *Science* **330**, 1231–1234. (doi:10.1126/science.1195421)
- 2 Discovery Networks 2008 *Time warp—dog drinking*. (<http://www.youtube.com/watch?v=63Ch2pNkZwU>).
- 3 Hiiemae, K. M. & Crompton, A. W. 1985 Mastication, food transport and swallowing. In *Functional vertebrate morphology* (eds M. Hildebrand, D. Bramble, K. Liem & D. Wake), pp. 262–290. Cambridge, MA: Belknap Press of Harvard University Press.
- 4 Thexton, A. J. & McGarrick, J. D. 1988 Tongue movement of the cat during lapping. *Arch. Oral Biol.* **33**, 331–339. (doi:10.1016/0003-9969(88)90066-0)